

Prenatal Diagnosis in Pericentric Inversion 6

J. Gazala, I. V. Amithkumar, J. Sabina, K.K. Praveena and J. Sujatha*

*Department of Clinical Genetics, Fetal Care Research Foundation, Chennai, Tamil Nadu, India
Telephone: +914424663144, E-mail: fcrfchennai@yahoo.com*

KEYWORDS Chromosome 6 Rearrangement. Prenatal Diagnosis. Microcephaly and Dysmorphism

ABSTRACT A four-year-old girl, the proband along with her mother in her subsequent pregnancy was referred to the genetic clinic for evaluation of global developmental delay with a normal karyotype study. On evaluation, dysmorphic features prompted to repeat the karyotype assessment. An unbalanced pericentric inversion of chromosome 6 in the index child was noticed. This was followed by identification of a balanced carrier status in the mother. Cytogenetic study using amniocentesis performed at our center for the subsequent pregnancy revealed balanced pericentric inversion of chromosome 6 in the fetus to that identified in the mother; a prenatal diagnosis was reached. The couple terminated the pregnancy following the diagnosis at 18 weeks.

INTRODUCTION

Chromosomal rearrangements can be classified as numerical and structural. Among the structural chromosomal rearrangements, deletion, duplication, and inversion are commonly described. In these inversions are less commonly reported rearrangement, however can assume significance when correlated with the clinical condition in an individual setting. Inversion is a two-break rearrangement involving a single chromosome in which a segment is reversed in position. They are of two types, namely pericentric and paracentric inversion. If it involves one arm, it is paracentric, and if the inversion segments involve the centromere, it is pericentric inversion. This report is about a rare cytogenetic abnormality due to a rearrangement in Chromosome 6. Literature clearly suggests important causal genes in the 6p region, which may be disrupted with either an isolated rearrangement or secondary to pericentric inversion. Reports by Poot (2009) and Anderlid (2003) in the chromosome 6p have identified dysmorphic face, non-progressive deficit of motor control, lack of speech development, reduced sensitivity to pain, with a known, complex interstitial deletion 6q14 described within a *de novo* pericentric inversion 6p11.2;q15. Another study by Field (1998) has identified a locus residing on chromosome 6p23-p21.3 pre-

disposing to specific reading disability (dyslexia). In one instance, duplication in 6p with minor dysmorphic signs, delayed psychomotor and speech development were reported by Vermeesch (2004). Anderlid (2003) and Vries (2001) have also described idiopathic mental retardation in rearrangements involving 6p.

CASE REPORT

A mother presently in her second pregnancy was referred for evaluation of her first-born girl child who is the proband. The age of proband during presentation at the clinic was 4 years and 7 months. Clinical examination revealed microcephaly; head circumference below fifth centile, dysmorphism such as triangular face, low set ears, abnormal pinnae, small mouth, high arched palate, abnormal dentition, clinodactyly and overlapping digits (Fig. 1). Clitoral hypertrophy and kyphoscoliosis of the spine were other findings identified in the phenotype. Antenatal history revealed a documented history of fetal distress secondary to intra uterine growth restriction was noted. Birth history revealed that she was born out of a preterm delivery by caesarian section at 36 weeks with a birth weight of 1.26kgs. The mother had no history of diabetes or pregnancy induced hypertension in the pregnancy. A clear history of failure to thrive with developmental delay from birth was known, however a karyotype done elsewhere reported normal study. The presence of a range of dysmorphic phenotype with IUGR and failure to thrive was a clue to work in the line of evaluating a chromosomal anomaly as an initial plan.

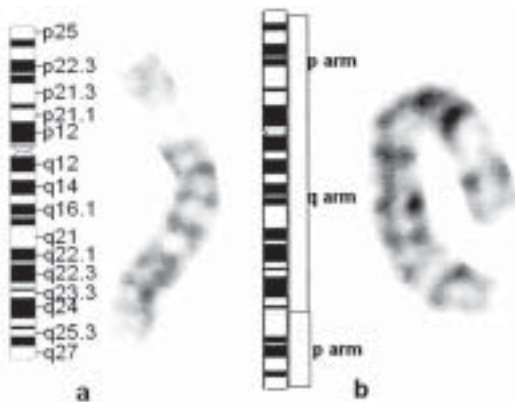
Correspondence:

Dr. Sujatha J
Consultant and Head,
Pediatrician and Dysmorphologist
Department of Medical Genetics, Fetal Care Research
Foundation, Chennai, Tamil Nadu, India

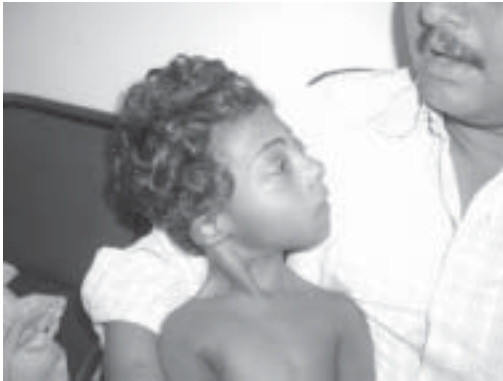

Fig. 1. Photograph of the index child

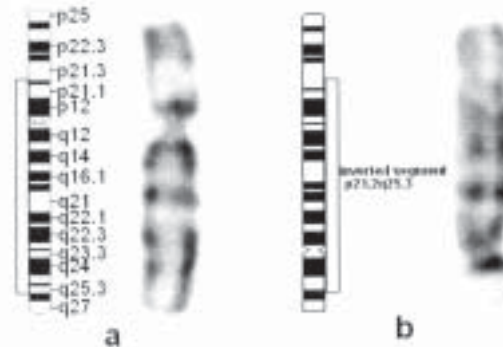
However, it is necessary to agree that there was a significant ambiguity in the results as the karyotype already done was reported normal. Considering a small probability of an interpretation error in karyotyping, the slide was analyzed. Following this, the index child was noted to have a recombinant chromosome 6 by a repeat assessment, described by $46,XX,rec(6)dup(6p)inv(6)(p21.2q25.3)mat$ (Fig. 2a). This revealed duplication from terminal end of 6p to p21, with and associated deletion from 6q25.3 to qter. Thereby the need for parental karyotype testing was explained and break points of rearrangement were confirmed. In that, the father's karyotype showed a normal $46,XY$



a-ideogram normal 6 and normal 6
b-ideogram inv and dup 6 abnormal inv and dup 6

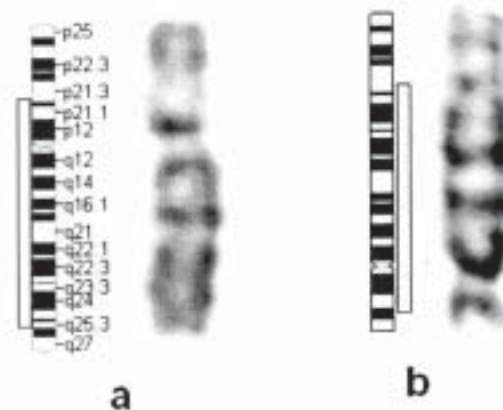
Fig. 2a. Partial karyotype of index child
 $46,XX,rec(6)dup(6p)inv(6)(p21.2q25.3)mat$
Duplication from 6pter to 6p21.2 with deletion from 6q25.3 to 6qter

complement. The mother had complement of $46,XX,inv(6)(p21.2q25.3)$ (Fig. 2b) which suggested that she is a carrier of balanced pericentric inversion of chromosome 6. Amniotic fluid analysis done at our center by amnio-



a-ideogram normal 6 and normal 6
b-ideogram 6 inv and abnormal 6

Fig. 2b. Partial karyotype of mother
 $46,XX,inv(6)(p21.2q25.3)$ - Pericentric inversion with breakage and reunion occurring at bands 6p21.2 and 6q25.3



a-ideogram normal 6 and normal 6
b-ideogram inv 6 and abnormal 6

Fig. 2c. Partial karyotype of fetus
 $46,XX,inv(6)(p21.2q25.3)mat$ - Pericentric inversion with breakage and reunion occurring at bands 6p21.2 and 6q25.3

centesis at 17th week revealed the fetus had a complement of $46,inv(6)(p21.2q25.3)mat$ with normal sex chromosomes (Fig. 2c). This suggests a balanced carrier status of the same rearrangement seen in the mother. Shaffer (2009) reported

Table 1: Reported cases of chromosome 6p rearrangements

<i>Clinical phenotype and presentation in chromosome 6p rearrangements</i>	<i>Published case report</i>
Dyslexia	Field (1998)
Low-set and dysplastic ears, ptosis of upper eyelids, small mouth with thin upper lip, cryptorchidism	Delatycki(1999) and Schinzel (2001).
Mental retardation	Anderlid(2003)and Vries (2001)
Dysmorphic signs and delayed psychomotor and speech development	Vermeesch (2004)
Short stature, IUGR, microcephaly and prominent forehead	Poot(2009) and Röthlisberger (1999)
Preterm IUGR, microcephaly, developmental delay, triangular face, low set ears, abnormal pinnae, small mouth, high arched palate, abnormal dentition, clinodactyly, overlapping digits. Clitoral hypertrophy and kyphosoliosis of the spine	Current report

the karyotype description of the entire family following current ISCN guidelines.

DISCUSSION

Inversions are balanced rearrangements that rarely cause problems in carriers unless if one of the break points involved has disrupted a gene of importance. However when balanced carriers transmit the rearrangement, it can result in a significant chromosomal imbalance in the offspring. Pairing and crossover during meiotic division occurs by loop formation between the homologous chromosomes to form recombinant products. The crossover determines the formation of a gamete either balanced or unbalanced. The simple rule is that if the inverted segment is small, because of cross over the deleted and duplicated segments is relatively large. The resultant products are therefore nonviable Turnpenny and Ellard (2005). On the contrary, if there is involvement of large inversion segment, deletion and duplicated segments are small. This scenario can result in a viable fetus, surviving to term and beyond and is probably seen in our case. Counseling should address the need for karyotype testing in the family and risk assessment of fetus in the ongoing pregnancy. The requisite for testing parental karyotype after an initial diagnosis in the index child should be stressed. The testing can elucidate the significance of the rearrangement identified in the family. Pericentric inversions have a likely recurrence of 5-10% with a previous affected child and if the risk is identified by a previous miscarriage, then a chance of 1% recurrence is advised; Turnpenny and Ellard

(2005). Clinically consistent phenotype in duplications from 6pter to 6p23 or 6p22 include intrauterine growth retardation, short stature, microcephaly, prominent forehead by Poot (2009), Röthlisberger (1999) and low-set and dysplastic ears, ptosis of upper eyelids, small mouth with thin upper lip, cryptorchidism in males and frequent occurrence of cardiac defects by Delatycki (1999) and Schinzel (2001). As previously reported, there is a similar phenotype description in this case with IUGR, microcephaly, speech difficulty, developmental delay and dysmorphic features. Clitoral hypertrophy and kyphoscoliosis are not previously reported. The couple opted to continue the pregnancy and agreed to be followed-up post natally. This is one instance where a clinical re-assessment proved to be of immense value to this family.

ACKNOWLEDGEMENT

Dr S.Suresh, Fetal Care Research Foundation

REFERENCES

- Field LL, Kaplan BJ 1998. Absence of Linkage of Phonological Coding Dyslexia to Chromosome 6p23-p21.3 in a Large Family Data Set. *Am J Hum Genet*, 63: 1448–1456.
- Delatycki MB, Voullaire L, Francis D, Petrovic V, Robertson A, Webber LR, Slater HR 1999. Directly inherited partial trisomy of chromosome 6p identified in a father and daughter by chromosome micro dissection, *J Med Genet*, 36: 335–338.
- Röthlisberger B, Kotzot D, Gnehm HE, Schinzel A 1999. 'Essentially pure' partial trisomy (6) (p23→pter) in two brothers due to maternal t(6;17) (p23;p13.3). *Am J Med Genet*, 85: 389–394

- De Vries BB, White SM, Knight SJ, Regan R, Homfray T, Young ID, Super M, McKeown C, Splitt M, Quarrell OW, Trainer AH, Niermeijer MF, Malcolm S, Flint J, Hurst JA, Winter RM 2001. Clinical studies on submicroscopic subtelomeric rearrangements: a checklist. *J Med Genet*, 38: 145–150
- Schinzel A 2001. *Catalogue of Unbalanced Chromosome Aberrations in Man*. 2nd Edition, Berlin and New York: Walter de Gruyter.
- Anderlid BL, Schoumans J, Hallqvist A, Stahl Y, Wallin A, Blennow E, Nordenskjold M 2003. Cryptic subtelomeric 6p deletion in a girl with congenital malformations and severe language impairment. *Eur Hum Genet*, 11; 89–92.
- Vermeesch JR, Thoelen R, Fryns JP 2004. A familial complex chromosome translocation resulting in duplication of 6p25. *Annales de Génétique*, 47: 275–280.
- Turnpenny P, Ellard S 2005. *Emery's Elements of Medical Genetics*, 12th Edition. Philadelphia: Elsevier Publication.
- Poot M, Slot RV, Leupert R, Beyer V, Passarge E, Haaf T 2009. Three de novo losses and one insertion within a pericentric inversion of chromosome 6 in a patient with complete absence of expressive speech and reduced pain perception. *European Journal of Medical Genetics*, 52: 27–30.
- Shaffer LG, Slovak ML, Campbell LJ (Eds.): ISCN 2009. *An International System for Human Cytogenetic Nomenclature*. Basel: Karger.